

COVER LETTER

**Suresh Chari**

**Professor**

**Department of Biochemistry**

**Director- IQAC, Research & Medical Education Technology, NKP SIMS&RC  
and LMH, Nagpur, Maharashtra**

4<sup>th</sup> September, 2022.

Respected Sir,

I am writing to submit our manuscript entitled EVALUATION OF OVARIAN PARAMETERS BEFORE AND AFTER CLOMIPHENE CITRATE IN EASTERN INDIAN WOMEN WITH PRIMARY INFERTILITY as an original article in **Panacea Journal of Medical Sciences**.

We measured the morphometric dimensions of bilateral ovaries of 50 subjects from Institute of post graduate Medical Education & Research, Kolkata, Infertility clinic.

The results suggest that the ovarian dimension as well as number of follicles changes significantly with administration of Clomiphene citrate.

Our study will offer readers information helpful for betterment of ovulation induction and treatment of infertility.

There is no funding and no conflict of interest in this work.

Sincerely

*Subhajit Halder*

Dr. Subhajit Halder

Corresponding Author.

18, Sahid Nalini Bagchi Road

P.O & P.S – Berhampore, Dist : Murshidabad

West Bengal. Pin : 742101

e-mail : [baptu.subhajit@gmail.com](mailto:baptu.subhajit@gmail.com)

Dr. Susmita Ghosh : First Author.

Dr. Oyndrila Sengupta : Second Author.

Dr. Srijit Narayan Chaudhuri: Third Author

# EVALUATION OF OVARIAN PARAMETERS BEFORE AND AFTER CLOMIPHENE CITRATE IN EASTERN INDIAN WOMEN WITH PRIMARY INFERTILITY

<sup>1</sup>Dr. Susmita Ghosh, <sup>2</sup>Dr. Oyndrila Sengupta, <sup>3</sup>Dr. Srijit Narayan Chaudhuri, <sup>4</sup>Dr. Subhajit Halder, <sup>5</sup>Dr. Arunabha Tapadar.

Running title: Changes in Ovarian parameters before and after Clomiphene.

<sup>1</sup>Assistant Professor, Department of Anatomy, Calcutta National Medical College.

<sup>2</sup> Demonstrator, Department of Anatomy, Calcutta National Medical College, posted at Murshidabad Medical College in detailment.

<sup>3</sup>Assistant Professor, Department of Anatomy, Shantiniketan Medical College.

<sup>4</sup> Demonstrator, Department of Anatomy, Murshidabad Medical College.

<sup>5</sup>Professor & Head, Department of Anatomy, Sarat Chandra Chattopadhyay Government Medical College.

Corresponding Author : Dr. Subhajit Halder

Mailing address: OBOSOR, 18 Sahid Nalini Bagchi Road. Berhampore-742101.

Murshidabad. West Bengal. India.

Email address: baptu.subhajit@gmail.com

Phn Number : +916296414419.

## **ABSTRACT**

**Background:** Women's biologic clocks do not synchronize with our relatively new societal clocks. Advancing female age is one of the "greatest enemies" of fertility. A reduction in hormones from the ovaries with age is therefore thought to decrease the chances for pregnancy. The **Clomiphene Citrate Challenge Test (CCCT)** is often used to predict the likelihood that a woman can achieve pregnancy using her own eggs.

**Aims:** To measure the changes of morphometric parameters of ovarian follicles and their numbers and compare the same before and after administration of Clomiphene citrate and also with aging.

**Materials & methods:** This interventional cohort study, performed on the women coming to the infertility clinic at Institute of Post Graduate Medical Education & Research, Kolkata with primary infertility of varying age groups. A total of 50 subjects were taken out for the study with their informed consent. Measurements of various parameters of the ovaries were done with Transvaginal ultrasonography. Comparison among them with respect to age, number, volume, length, breadth both before and after ovulation induction with Clomiphene citrate were made.

**Result:** Statistically significant decline in number of follicle and ovarian volume was seen after 30 years of age on both sides indiscriminately. The volume and length of ovaries and the follicle number are significantly increased following Clomiphene administration. Though the breadth is not significantly changed.

**Conclusion:** The study confirms that transvaginal ultrasound can provide a reliable measure in monitoring the follicular growth and ovulation. It also proves that clomiphene is one of the best first line drug for induction of ovulation.

Key words: ovarian follicle, ovulation, Clomiphene citrate, primary infertility, ovulation induction.

## **INTRODUCTION**

Transvaginal Ultrasound is currently the gold standard for assessing follicular growth. With the introduction of pelvic ultrasound in the 1980s, non-invasive assessment of ovarian morphology became possible. With advances in technology in particular that of TVS, ultrasound has replaced laparotomy and X-Ray pelvic pneumogynaecography in the diagnosis of PCOS [1]. The static B scanners of the mid 1960s allowed visualization of ovarian enlargement as well as of cysts > 1 cm in diameter [2]. The poor resolution of the ultrasound equipment used in the early 1970s, permitted visualization of the ovarian outline only. However, the use of a single dimension may lead to false positive results when the full bladder compresses the ovary or false negative results when the ovaries are spherical in shape. Thereafter the development of grey scan equipment in the 1970s and real time sector scanners in the 1980s, improved resolution and for the first time, follicles or cysts < 1 cm could easily be recognized.[3] In 1981, Swanson et al described PCO as enlarged and rounded with a mean volume of 12 cm<sup>3</sup> and containing an increased number of small follicle (2 – 8 mm) encircling the ovarian cortex.[4] In 1985, new criteria based on TA ultrasound required 10 or more cysts of 2 – 8 mm in diameter arranged peripherally around an echodense stroma.[5] These criteria have remained in widespread use even after the introduction of TVS, a decade later. Ultrasound studies have demonstrated that approximately 20% of young women have polycystic ovaries.

### **Materials and methods**

**Place of Study:** Infertility Clinic of department of Gynaecology & Obstetrics of SSKM and IPGMER, Kolkata.

**Period of Study:** Cases were selected from the month of March 2008 to August 2009.

**Sample Size: 50**

## **Study population:**

### Inclusion criteria:

1. Female patients
2. Age group of 19 – 36 years.
3. Primary infertility.
4. Defect in ovulation
5. Patients with PCOD

### Exclusion criteria:

1. Patients with co-morbidities.
2. Patients with secondary infertility.
3. Debilitated or moribund patients.
4. Patients under Contraceptives.
5. Primary infertility due to other causes
6. Menopause
7. Unmarried subject

The main outcome measures were changes in the ovarian parameters and follicle status with age and following clomiphene therapy.

## **Methodology**

The patients were examined thoroughly in the infertility clinic of the same hospital. Full history was taken with special reference to menstrual history and treatment history. General survey was done with special reference to body weight, excess body hair, hirsutism, any pelvic mass, etc.

Transvaginal ultrasonography was done – baseline folliculometry (before treatment with clomiphene) and post treatment folliculometry.

Before Application of Clomiphene: Study of ovarian size, volume and development of follicles followed by rupture, if any, with alternate day transvaginal ultrasonography was done. Study started from Day 9 of menstrual cycle.

Application of Clomiphene: 100 mg orally daily from Day 3 to Day 7 for 1 cycle.

After Application of Clomiphene: Similar alternate day transvaginal sonography to observe changes, if any, in the same parameters, starting from Day 9 of the same cycle in which clomiphene was given.

**Parameters seen:**

1. Ovarian Length (Right & Left).
2. Ovarian Breadth (Right & Left).
3. Ovarian Height (Right & Left).
4. Ovarian volume (Right & Left).
5. Number of follicles in each ovary.

**Operational Definitions:**

a. Transvaginal Ultrasonography

Toshiba Xario Model ultrasonography machine was used. It is performed by a registered medical sonologist. Preparation of the patient: Patients need to empty the urinary bladder before transvaginal sonography. During the sonogram, the patient lies on the examination table in supine position with knees flexed. Gel is applied on the vaginal probe and then covered by a condom. The gel helps elimination of the formation of air pockets between the transducer and the organ examined. The sonographer introduces a probe into the patient's vagina and presses the transducer against the part examined, moving from one area to another as necessary to view the uterus and ovaries. Sonography usually is a painless procedure. However, one may experience some discomfort as the sonographer guides the transducer. Transvaginal imaging utilizes a higher frequency imaging achieving better resolution of the ovaries.[6]

b. 3 – D Ultrasound:

To avoid the difficulties in outlining or measuring ovarian size, 3 – D ultrasound has been proposed using a volumetric probe (9) or a manual survey of the ovary. 3 – D ultrasound has been used to measure ovarian and stromal volumes providing information that is not available from 2 – D ultrasound. Data can be transferred to a computer and analysed later.[7]

c. X – Rays:

are a form of radiation which can cause chemical changes in the tissue. Ultrasound was a different form of radiation, called non-ionising radiation, which does not produce chemical changes in the tissues and is considered safe.

**Statistical Analysis:**

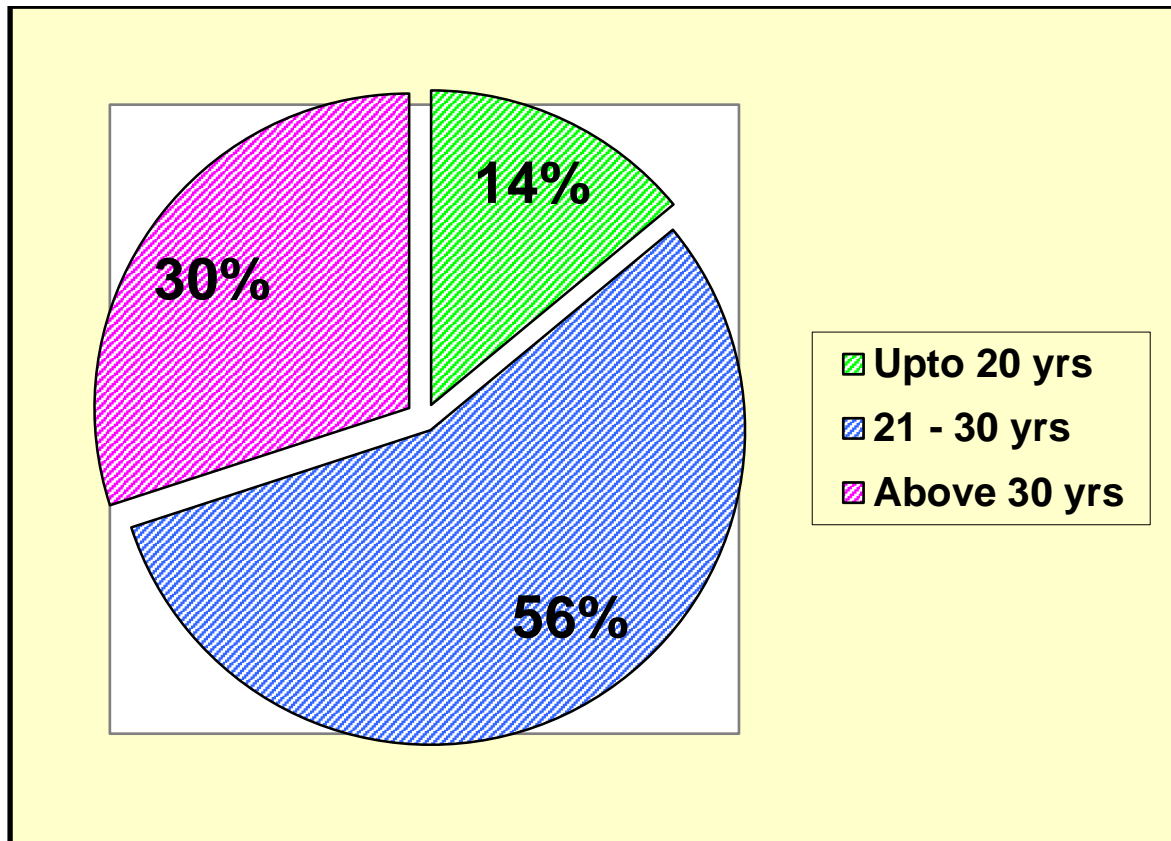
Analysis of the data were done using STATISTICA version 6 (Tulsa, Oklahoma; STATSOFT.Inc;2001)

**Ethical clearance:**

Obtained from Institutional ethical committee of IPGME&R, memo no. Inst./IEC/320, 31/03/2008.

## Results

**Table/Fig. 1: Age distribution of patients approaching the infertility clinic**



## Volume of the ovary with age (average of rt. & lt. ovaries)

The volume of the ovary decreases after 30 years. So 30 years has been taken as the cut off age.

The decrease in volume indicates a fall in ovarian reserve and number of eggs. No significant difference was found between the right & left ovaries.



**Table 2: Change in the volume of ovaries with age**

Age range	No. of patients	Vol. of ovary (average of rt. & lt. ovaries)
19- 20 yrs.	7	8.87 cc
21 – 30 yrs.	28	8.83 cc
30-36 yrs.	15	5.32 cc
<b>Total</b>	50	

**Table 3: Volume of the ovary before & after Clomiphene therapy**

Volume of ovary (cc)					
Before clomiphene	Range	Mean	Median	Std. Devn.	p value for average volume before & after clomiphene = 0.000341
<b>Right</b>	2.74 -7.63	8.38	8.77	3.26	
<b>Left</b>	3.15 -14.44	7.94	7.71	2.92	
<b>Average</b>	2.99 -13.61	8.16	8.45	2.90	
After Clomiphene	Range	Mean	Median	Std. Devn.	
<b>Right</b>	2.39 -18.47	9.22	9.59	3.60	
<b>Left</b>	2.95 -13.89	8.55	8.73	2.99	
<b>Average</b>	2.67 -13.43	8.89	9.58	3.05	

The change in volume is usually insignificant. However, in the present study, the volume change is significant as we have included several cases of PCOD. In these cases, there is a rise of ovarian volume due to Clomiphene therapy.

**Table 4: Length of the ovary before & after Clomiphene therapy (average of rt. & lt. ovaries)**

<b>Length of ovary (cm)</b>					
<b>Before clomiphene</b>	<b>Range</b>	<b>Mean</b>	<b>Median</b>	<b>Std. Devn.</b>	<b>p value for average length before &amp; after clomiphene = 0.000000</b>
<b>Right</b>	2.30 – 4.90	3.66	3.75	0.66	
<b>Left</b>	2.20 – 4.80	3.56	3.80	0.63	
<b>Average</b>	2.25 – 4.70	3.61	3.78	0.61	
<b>After Clomiphene</b>	<b>Range</b>	<b>Mean</b>	<b>Median</b>	<b>Std. Devn.</b>	
<b>Right</b>	2.40 – 5.00	3.82	4.00	0.65	
<b>Left</b>	2.00 – 4.80	3.70	3.90	0.68	
<b>Average</b>	2.35 – 4.80	3.76	3.90	0.64	

The change of length is significant with Clomiphene therapy.

**Table 5: Breadth of the ovary before & after Clomiphene therapy (average of rt. & lt. ovaries)**

<b>Breadth of ovary (cm)</b>					
<b>Before clomiphene</b>	<b>Range</b>	<b>Mean</b>	<b>Median</b>	<b>Std. Devn.</b>	<b>p value for average breadth before &amp; after clomiphene = 0.204613</b>
<b>Right</b>	1.40 – 4.20	2.09	2.00	0.53	
<b>Left</b>	1.40 – 3.40	2.02	2.00	0.46	
<b>Average</b>	1.40 – 3.50	2.05	1.98	0.44	
<b>After Clomiphene</b>					
<b>Range</b>	<b>Mean</b>	<b>Median</b>	<b>Std. Devn.</b>		
<b>Right</b>	1.20 – 4.40	2.18	2.10	0.57	
<b>Left</b>	1.40 – 2.90	2.09	2.10	0.36	
<b>Average</b>	1.30 – 3.60	2.14	2.10	0.43	

There was no significant change with Clomiphene therapy.

**Table/Fig. 7 : Total number of follicles in both ovaries before & after Clomiphene therapy**

<b>Number of ovarian follicles</b>					
<b>Before clomiphene</b>	<b>Range</b>	<b>Mean</b>	<b>Median</b>	<b>Std. Devn.</b>	<b>p value for average no. of follicles before &amp; after clomiphene = 0.000028</b>
<b>Right</b>	0.00 – 6.00	3.80	4.00	2.13	
<b>Left</b>	0.00 – 6.00	3.70	3.50	2.12	
<b>Total</b>	0.00 –12.00	7.50	7.50	4.01	
<b>After Clomiphene</b>					
<b>Range</b>	<b>Mean</b>	<b>Median</b>	<b>Std. Devn.</b>		
<b>Right</b>	0.00 – 7.00	4.00	6.00	2.45	
<b>Left</b>	0.00 – 7.00	4.00	6.00	2.35	

<b>Total</b>	1.00 –13.00	8.00	12.00	4.71	
--------------	-------------	------	-------	------	--

In PCOD cases, many follicles are small & immature and may be  $\geq 10$  in number. In the present study, significant follicles were taken to be  $> 10$  mm in maximum dimension. Folliculometry was done from day 9, on alternate days till rupture of follicles if any. If no follicles ruptured, measurements were continued till day 21. Unruptured follicles became atretic.

No. of follicles before Clomiphene = 7.50 follicles.

No. of follicles after Clomiphene = 8.00 follicles

## Discussion

Age changes in ovarian volume as measured by Trans vaginal Sonography (TVS):

The volume of the ovary decreases with age. However, this is not just a perimenopausal feature. In the present study, a gradual decrease in ovarian volume was observed between the ages of 19 and 36 years, the average ovarian volume dropping from 8.87cc to 5.32cc. A sharp decline in ovarian volume has been found after the age of 30 years. Ovarian volume was unrelated to patient weight. In present study each ovary was measured in three dimensions and ovarian volume was calculated using the **prolate ellipsoid formula (Length X Height X Width X 0.523)**. It supports the work of *E. J. Pavlik et al* , who found a statistically significant decrease in ovarian volume in each decade of life from age 30 to age 70.[8] They have set the upper limit of normal for ovarian volume at 20 cm<sup>3</sup> in pre-menopausal women and 10 cm<sup>3</sup> in post menopausal women.

No significant difference was found between the volumes of right & left ovaries. The ovarian volume varied from 5.32 cc to 8.87 cc with an average of 7.67 cc. This tallies with the data of *Farzana et al.* [9]

Most of the couples attending the infertility clinic at the Dept. of Gynecology, I.P.G.M.E.&R. were referred cases from other institutions. They had already spent a considerable amount of time and money over various modalities of treatment with no results. The mental pressure on the concerned couples was considerable and they had come to this referral centre with a lot of hope. All previous investigations were reviewed to prevent unnecessary duplication of test.

In humans therefore, oocytes are established in the ovary before birth, and may be dormant awaiting initiation for up to 50 years. [10]

The oocyte in a follicle is in the stage of a primary oocyte. The nucleus of such an oocyte is called a germinal vesicle. Meiosis I is completed just prior to ovulation which results in the formation of the mature Graafian Follicle. Meiosis II is completed around fertilization forming the mature ovum. [11,12]

The mean diameter of the dominant follicle is 20mm before ovulation, the mean volume 3.0 ml, and the growth rate of follicles 1-3mm/24 hr. Ovulation occurred within 24 hrs of the LH peak and within 48 hours of the blood estrogen peak.

Advancing female age is one of the “greatest enemies” of fertility. This contrasts the most males who can father children for their entire lives. If one graphs female age against declining fertility, there is a direct relationship which culminates in the menopause. [13,14]

The human ovaries become unresponsive to gonadotropins<sup>38</sup> with advancing age and their function declines, so that sexual cycles disappear (menopause). This unresponsiveness is associated with and probably caused by a decline in the number of primordial follicles, which becomes precipitous at the time of menopause .

**Causes of infertility in the present study – All the cases were due to failure of ovulation.**

However, none of the cases were due to primary ovarian failure (total absence of follicles).

Follicles were formed in all cases, with or without the use of clomiphene. In most cases, the infertility was due to inadequate growth of the follicle, absence of dominant follicle, failure of rupture and premature atresia.

The present study addressed the problem of anovulation. The cases were followed up in a particular cycle by transvaginal ultrasonography to assess the number & size of the maturing follicles up to ovulation. This was done both before and after administration of clomiphene.

### **The use of Clomiphene citrate for induction of ovulation**

Clomiphene citrate (CC) is a synthetic, non steroidal oestrogen antagonist drug which has been in use since the 1970's. It binds to both oestrogen receptor  $\alpha$  and  $\beta$ . It induces gonadotropin secretion in women by blocking oestrogenic feedback inhibition of pituitary. The amount of LH / FSH released at each secretory pulse is increased. In response, the ovaries enlarge and ovulation occurs if the ovaries are responsive to gonadotropins. Antagonism of peripheral action of oestrogen results in hot flushes. The endometrium and cervical mucus may be modified.

Clomiphene is useful in women with oligomenorrhoea and amenorrhoea with intact hypothalamo – pituitary – ovarian axis. If the patient is anovulatory, CC is often used before diagnostic procedures continue. Some authorities prefer to initiate treatment with 50 mg once daily 5 days starting from the 5<sup>th</sup> day of the cycle. Treatment was given monthly. If 1 – 2 months treatment did not result in conception, the daily dose was doubled for 2 – 3 cycles up to a maximum of 200 mg/day.

In the present study, clomiphene alone was used with similar results. Similar findings have been reported by *Nasrullah, et al.* [15]

Nausea, vomiting, vasomotor flushes, bloating sensation were the adverse effects of clomiphene citrate therapy in few cases of this study.

Changes in the ovary after Clomiphene therapy:

Increase in ovarian dimensions & volume after treatment with Clomiphene as measured by TVS

In the previous sections it was seen that the ovarian volume gradually decreases over the lifetime of the individual. The decline was specially rapid after the age of 30 years. Clomiphene therapy increased the ovarian volume due increased secretion of pituitary gonadotropins. This increase was due to both increased folliculogenesis and an increase in the ovarian stroma.

Thus clomiphene compensates for the age changes in the ovary and brings about a greater chance of conception even in the ageing ovary.

In the present study, the size of the ovary increased after clomiphene therapy in all three axes (length, breadth & height). The average length increased from 3.61cm to 3.76cm, the breadth from 2.05cm to 2.14cm, and the height from 2.04cm to 2.05cm. While the individual axial lengths showed a modest increase, the volume increased from 8.16cm to 8.89cm. Similar work has been carried out by Goswami et al in 1988 [16, and Fossum et al in 1990 [17]. Measurements of the ovaries in younger age groups are also available from the data of Haber et al in 1994.[18]

Change in total number of follicles before and after treatment with Clomiphene as measured by TVS: It is not economically feasible to carry out sonographic folliculometry in several cycles for each patient. Therefore, one or at the most two cycles may be selected for the purpose. In any particular cycle, folliculometry was done on alternate days from day 9 till rupture. If there is no evidence of rupture, the study was carried out till day 21. This study is expensive because it has to be done both before and after clomiphene therapy.

In the present study, the number of ovarian follicles ranged from 0 to 12 before stimulation with clomiphene and from 1 to 13 after stimulation.

Previous workers have divided such cases into three groups based on the sum of ovarian follicles in both ovaries – inactive (< 5 follicles), normal (5 – 15 follicles) and polycystic

like ovaries (> 15 follicles). The number of follicles present before stimulation was found to be a better predictor of outcome than ovarian volume or age alone. Patients with inactive ovaries were found to have a poor response to IVF treatment (*Tomas et al*).[19]

### **Solutions after failure of treatment of infertility**

Despite all efforts, some couples are not benefited by infertility therapy. For these cases there remain the options of assisted reproduction measures, surrogate pregnancy and adoption.

### **The future:**

The future of reproductive technology is opening up at a rapid rate. Selective culture of embryos, screening for birth defects at the primordial stage and genetically engineered fetuses are looming on the horizon. The womb and the mother's lap may be replaced by culture solutions and incubators. The role of the individual parents in conceiving a child is likely to decrease with unknown consequences for the child. A compromise will have to be made between conception of perfect children and parental and child bonding. The challenges of the future are likely to bring forth unique solutions to the age old process of natural childbirth and rearing.

### **Conclusion:**

The present study has shown that the ovarian reserve declines with age. Both the size of the ovary and the number of follicles are gradually reduced after the second decade. The decline however is abrupt after the age of 30. The increased latency of meiosis in the developing ovarian follicle predisposes it to various disruptive influences. It would therefore seem to be a wise idea to contemplate the completion of one's family by the third decade. In the present study, we have studied the dimensions of the ovary across the ages of 19 – 36 years. The gradual decline in



ovarian function was evident on transvaginal sonography (TVS). The effect of clomiphene was dramatic, with recruitment of follicles and an increase in size of one or more dominant follicles.

## REFERENCES:

1. Weigen JF, Stevens GM. Pelvic pneumography in the diagnosis of polycystic disease of the ovary, including Stein-Leventhal syndrome. A comparison with the normal pelvic pneumogram. *Am J Roentgenol Radium Ther Nucl Med.* 1967 Jul;100(3):680-7. doi: 10.2214/ajr.100.3.680. PMID: 6028976.
2. Balen, Adam & Laven, Joop & Tan, Seang & Dewailly, Didier. (2003). Ultrasound assessment of the polycystic ovary: International Consensus Definitions. *Human reproduction update.* 9. 505-14. 10.1093/humupd/dmg044.
3. Çıracı S, Tan S, Özcan AŞ, Aslan A, Keskin HL, Ateş ÖF, Akçay Y, Arslan H. Contribution of real-time elastography in diagnosis of polycystic ovary syndrome. *Diagn Interv Radiol.* 2015 Mar-Apr;21(2):118-22. doi: 10.5152/dir.2014.14094. PMID: 25616270; PMCID: PMC4463318.
4. Swanson , M. , Sauerbrie , E.E . an d Cooperberg , P.L .1981. Medica l implications of ultrasonically detected polycystic ovaries. *Clin. Ultrasound,* 9 , 219-222 .
5. Gyliene A, Straksyte V, Zaboriene I. Value of ultrasonography parameters in diagnosing polycystic ovary syndrome. *Open Med (Wars).* 2022 Jun 20;17(1):1114-1122. doi: 10.1515/med-2022-0505. PMID: 35799603; PMCID: PMC9210988.
6. Moorthy RS. TRANSVAGINAL SONOGRAPHY. *Med J Armed Forces India.* 2000 Jul;56(3):181-183. doi: 10.1016/S0377-1237(17)30160-0. Epub 2017 Jun 10. PMID: 28790701; PMCID: PMC5532046.

7. Po-Mui Lam, Nick Raine-Fenning, The role of three-dimensional ultrasonography in polycystic ovary syndrome, *Human Reproduction*, Volume 21, Issue 9, 1 September 2006, Pages 2209–2215, <https://doi.org/10.1093/humrep/del161>
8. [Pavlik EJ](#), [DePriest PD](#), [Gallion HH](#), [Ueland FR](#), [Reedy MB](#), [Kryscio RJ](#), [van Nagell JR Jr](#) - Ovarian volume related to age. *Gynecol Oncol*. 2000 Jun;**77**(3):410-2.
9. Fauzia Farzana, Marina Babtist, Saima Ameer, Yasir Ameen – Ultrasound evaluation of ovarian size in normal menstruating women. *Biomedica* 2007; 23: 141 – 3.
10. Johnson J, Bagley J, Skaznik-Wikiel M, Lee H, Adams G, Niikura Y, Tschudy K, Tilly J, Cortes M, Forkert R, Spitzer T, Iacomini J, Scadden D, Tilly J - Oocyte generation in adult mammalian ovaries by putative germ cells in bone marrow and peripheral blood. *Cell* . 2005; 122 (2): 303–15.
11. Gougeon A - Regulation of ovarian follicular development in primates: facts and hypotheses. *Endocr Rev* 1996; 17 (2): 121–55.
12. Gougeon A - Dynamics of follicular growth in the human: a model from preliminary results. *Hum Reprod* 1986; 1 (2): 81–7.
13. Johnson J, Canning J, Kaneko T, Pru J, Tilly J - Germline stem cells and follicular renewal in the postnatal mammalian ovary. *Nature* 2004; 428 (6979): 145–50.
14. Van den Hurk R, Zhao J - Formation of mammalian oocytes and their growth, differentiation and maturation within ovarian follicles. *Theriogenology* 2005; 63 (6): 1717–51.
15. Nasrullah FD, Khan A, Soomro N. Outcome of ovulation induction in Polycystic Ovarian Syndrome. *Med Channel* 2005; 11(1): 68 – 9.

16. Goswami RK, Campbell S, Royston JP, Bhan V, Battersby RH, Hall VJ, Whitehead MI, Collins WP – Ovarian size in post menopausal women. *British Journal of Obstetrics and Gynaecology* 1988.
17. [Fossum GT](#), [Vermesh M](#), [Kletzky OA](#) - Biochemical and biophysical indices of follicular development in spontaneous and stimulated ovulatory cycles. *Obstet Gynecol.* 1990 Mar; 75(3 Pt 1):407-11.
18. Haber HP, Mayer EI – Ultrasound evaluation of uterine and ovarian size from birth to puberty. *Pediatric Radiology* 1994; 24: 11 – 13.
19. Tomas C, Nuojuua – Huttunen S, Martikainen H – Pretreatment transvaginal ultrasound examination predicts ovarian responsiveness to gonadotrophins in in-vitro fertilization. *Medline*; PMID: 9070699.